

Review Article

A systematic review of cases of CNS demyelination following COVID-19 vaccination

Ismail Ibrahim Ismail^{a,*}, Sara Salama^{b,1}

^a Department of Neurology, Ibn Sina Hospital, Kuwait

^b Department of Neurology and Psychiatry, University of Alexandria, Alexandria, Egypt

ARTICLE INFO

Keywords:

COVID-19
SARS-CoV-2
Vaccine
Demyelinating disease
Multiple sclerosis
Transverse myelitis

ABSTRACT

Background: Since the emergency use approval of different types of COVID-19 vaccines, several safety concerns have been raised regarding its early and delayed impact on the nervous system.

Objective: This study aims to systematically review the reported cases of CNS demyelination in association with COVID-19 vaccination, which has not been performed, to our knowledge.

Methods: A systematic review was performed by screening published articles and preprints of cases of CNS demyelination in association with COVID-19 vaccines in PubMed, SCOPUS, EMBASE, Google Scholar, Ovid and medRxiv databases, until September 30, 2021. This study followed PRISMA guidelines. Descriptive findings of reported cases were reviewed and stratified by demographic and clinical findings, diagnostic work-up, management, and overall outcome.

Results: A total of 32 cases were identified, with female predominance (68.8%) and median age of 44 years. Eleven cases were reported after Pfizer vaccine, 8 following AstraZeneca vaccine, 6 following Moderna, 5 following Sinovac/ Sinopharm vaccines, and one following each of Sputnik and Johnson&Johnson vaccines. The majority of cases (71.8%) occurred after the first dose of the vaccine, with neurological symptoms manifesting after a median of 9 days. The most common reported presentations were transverse myelitis (12/32) and MS-like pictures (first diagnosis or a relapse) in another 12/32 cases, followed by ADEM- like (5/32), and NMOSD- like (3/32) presentations. History of a previous immune-mediated disease was reported in 17/32 (53.1%) cases. The mRNA-based vaccines resulted in the greatest number of demyelinating syndromes (17/32), followed by viral vector vaccines (10/32), and inactivated vaccines (5/32). Most MS-like episodes (9/12) were triggered by mRNA-based vaccines, while TM occurred following both viral vector and mRNA-based vaccines. Management included high dose methylprednisolone, PLEX, IVIg, or a combination of those, with a favorable outcome in the majority of case; marked/complete improvement (25/32) or stabilized/ partial recovery in the remaining cases. **Conclusion:** This systematic review identified few cases of CNS demyelination following all types of approved COVID-19 vaccines so far. Clinical presentation was heterogenous, mainly following the first dose, however, half of the reported cases had a history of immune-mediated disease. Favorable outcome was observed in most cases. We suggest long-term post-marketing surveillance for these cases, to assess for causality, and ensure the safety of COVID-19 vaccines.

1. Introduction

Coronavirus disease 2019 (COVID-19) pandemic, caused by severe acute respiratory syndrome coronavirus 2 (SARS-CoV-2), had a devastating impact on public health, global economy, and social life worldwide. In response, there has been an unprecedented effort for the rapid development of vaccines, as the most effective tool in reducing

morbidity and mortality (World Health Organisation, 2021).

Despite the challenges related to the development of the vaccine, an emergency use approval has been granted for COVID-19 vaccines by the end of 2020, by different regulatory authorities around the world before the completion of conventional phases of clinical trials.

Currently, there are four types of vaccines against COVID-19; whole virus (live attenuated, inactivated), nucleic acid (mRNA, DNA), viral

* Corresponding author at: Ibn Sina Hospital, Gamal Abdel Nasser Street, Sabah Medical Area, Safat, Kuwait.

E-mail address: dr.ismail.ibrahim2012@gmail.com (I.I. Ismail).

¹ Authors contributed equally to manuscript.

vector (non-replicating, replicating), and protein-based (subunit, virus-like particle) vaccines. Whole virus vaccines use a weakened or inactivated form of SARS-CoV-2 to trigger protective immunity; the nucleic acid vaccines introduce mRNA or DNA coding for SARS-CoV-2 spike protein into the cells, to induce cells to produce antibodies; viral vector vaccines use a chemically weakened virus (e.g. adenovirus) to insert the code for SARS-CoV-2 antigens into the cells; while protein subunit vaccines are based on the Spike protein or its antigenic fragments (Nagy and Alhatlani, 2021).

As of July 2021, there are 18 approved COVID-19 vaccines in use around the world, 184 COVID-19 vaccine candidates in pre-clinical development, and 105 in clinical development (Ndwandwe and Wiysonge, 2021). Although initial data on efficacy and safety were encouraging, several concerns have been raised regarding its immediate, intermediate, and long-term sequelae. The commonly reported adverse events are usually mild and self-limited, including injection site reaction, headache, fever, fatigue, and myalgia (Hernández et al., 2021). However, and as global vaccination advanced, several cases of neurological syndromes have been reported in temporal relationship with the vaccination, although causality could not be made with absolute certainty (Goss et al., 2021; Lu et al., 2021a).

Interim reports of safety data from the clinical trials of several approved vaccines have been published. Recombinant ChAdOx1 nCoV-19 vaccine had been associated with three instances of acute transverse myelitis (ATM) during the trial phase (Mahase, 2020; Ling et al., 2021). Moreover, Centers for Disease Control (CDC)'s Vaccine Adverse Event Reporting System (VAERS) reported neurological complications in relation to Pfizer-BioNTech, Moderna and Johnson & Johnson's COVID-19 vaccines in 254 cases (2.69%); of which, 9 had ATM, and 6 had acute disseminated encephalomyelitis (ADEM) (Goss et al., 2021).

In literature, a wide variety of autoimmune neurological syndromes have been reported following different types of viral vaccinations. The most commonly reported vaccines that were associated with CNS demyelination were influenza, human papilloma virus (HPV), hepatitis A or B, rabies, measles, and rubella (Karussis and Petrou, 2014a).

As it is crucial to evaluate the long-term post-marketing safety data, particularly events affecting the nervous system, we systematically reviewed the current literature of reported cases of CNS demyelination post-COVID-19 vaccination. This review described their clinical, laboratory, and imaging findings, in addition to their diagnostic work-up and management, which has not been performed, to the best of our knowledge.

2. Methods

2.1. Design

This systematic review was carried out in accordance with Preferred Reporting Items for Systematic Reviews and Meta-analysis (PRISMA) guidelines. Data from PubMed, SCOPUS, EMBASE, Google Scholar, Ovid, and medRxiv databases were searched. We aimed to identify relevant articles reporting any form of CNS demyelination in association with any type of approved COVID-19 vaccines, until September 30, 2021.

2.2. Search strategy

A pre-specified searching strategy consisted of a variation of keywords of relevant medical subject headings (MeSH) and keywords, including: "COVID-19", "SARS-CoV-2", "vaccine", "vaccination", "mRNA vaccine", "AstraZeneca COVID-19 vaccine", "ChAdOx1 nCoV-19 vaccine", "AZD1222 vaccine", "Janssen COVID-19 vaccine",

"Johnson & Johnson COVID-19 vaccine", "Ad26.COV2 vaccine", "Pfizer-BioNTech COVID-19 vaccine", "BNT162b2", "Moderna COVID-19 vaccine", "Sinovac COVID-19 vaccine", "demyelinating disease", "demyelination", "acute disseminated encephalomyelitis", "transverse myelitis", "multiple sclerosis", "neuromyelitis optica". Moreover, we hand-searched additional relevant articles that were referenced in the included studies.

2.3. Inclusion criteria

We included all peer-reviewed publications and preprints that reported any form of CNS demyelination in association with any type of COVID-19 vaccines, including but not limited to case reports and case series that met the following criteria: (i) reports of early or delayed CNS demyelination after COVID-19 vaccine; (ii) reports of possible association of cases fulfilling the diagnostic criteria of multiple sclerosis (MS), transverse myelitis (TM), neuromyelitis optica spectrum disorder (NMOSD), or myelin oligodendrocyte glycoprotein antibody disease (MOGAD), and COVID-19 vaccines; and (iii) studies published in English.

2.4. Exclusion criteria

Reports that lacked supporting imaging findings, laboratory, or clinical evidence of CNS demyelination after vaccination were excluded from this study. We also excluded review papers, viewpoints, commentaries, and editorials, unless reporting a case of demyelination. Reports of CNS demyelination during clinical trials were also excluded due to lack of clinical data. The review was restricted to studies published in English.

2.5. Data extraction

Titles and abstracts of all identified studies were screened for relevance by the two reviewers, followed by full-text screening of the deemed eligible articles. The same reviewers then extracted data on the following parameters: article title, authors, publication year, age and gender of the patients, COVID-19 vaccine related information, onset of neurological symptoms, findings of neurological examination, MRI findings, laboratory work-up, CSF analysis, treatment, and clinical outcome.

2.6. Statistical analysis

Qualitative data were described in percentages and numbers. Quantitative data were described using range (minimum and maximum), and median. Significance of the obtained results was judged at the 5% level, but it could not be calculated due to insufficient data. A meta-analysis was planned to evaluate the association of the demographic findings, clinical, radiological and laboratory findings and outcomes, but it could not be performed due to lack of sufficient data.

3. Results

Our systematic search resulted in an initial number of 506 of potentially relevant articles, following duplicates removal. Articles were screened by title and abstract, and 42 articles were deemed eligible, after applying the inclusion/exclusion criteria to the full-text documents. Of which, 25 single-case reports and 1 case-series were included in the final systematic review. The flowchart for the study selection is shown in Fig. 1.

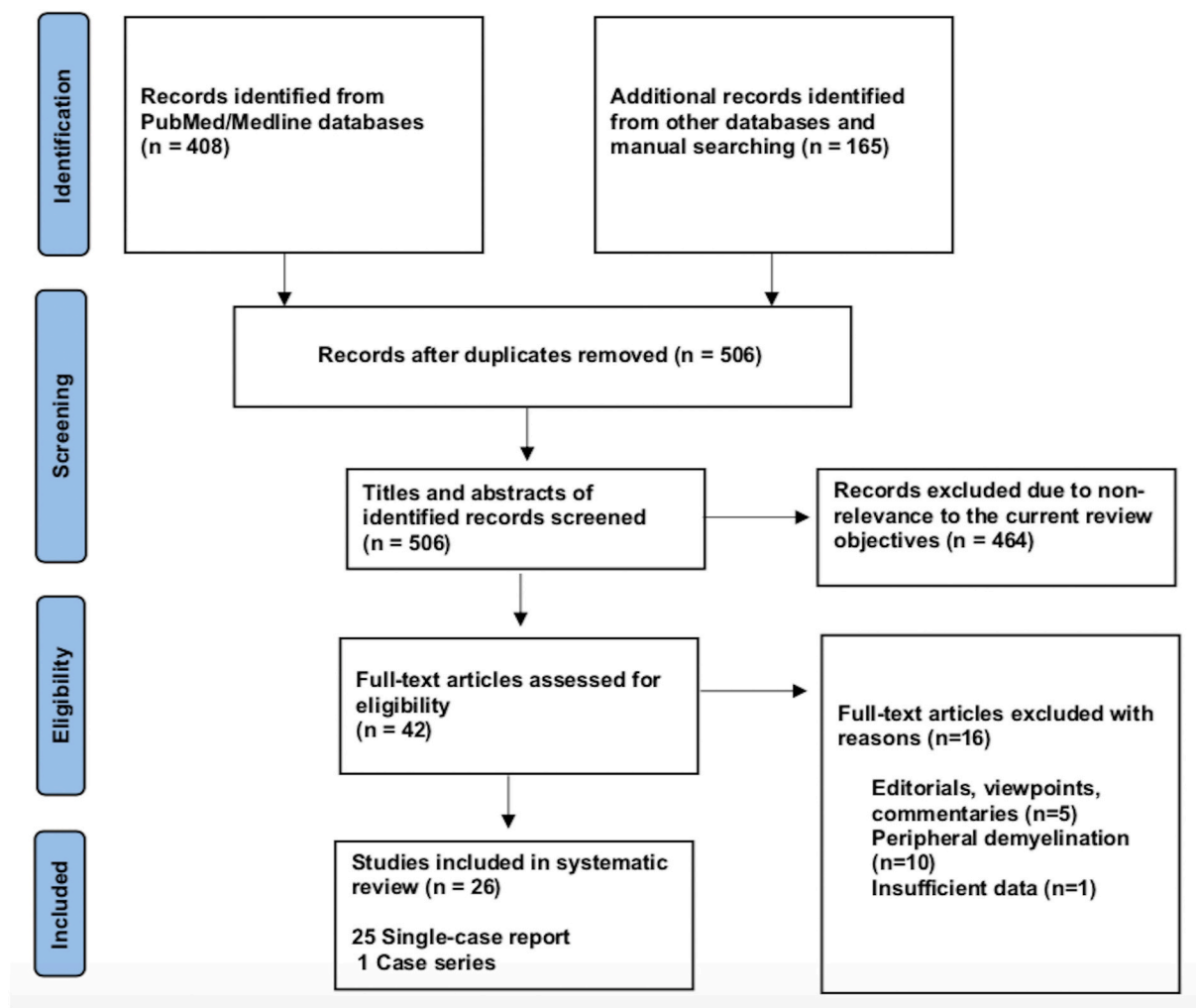


Fig. 1. Flowchart of literature inclusion in accordance with PRISMA guidelines.

3.1. Demographic data

A total of 32 cases were reported as of September 30, 2021; 11 cases occurred following Pfizer-BioNTech vaccine, 8 following Oxford-AstraZeneca vaccine, 6 following Moderna, 5 following Sinovac/ Sinopharm vaccines and one following each of Sputnik and Johnson & Johnson vaccines. The majority of cases were females; 22/32 (68.8%), with a ratio of (2.2:1). The reported cases came from 12 countries; 11 cases from USA, 4 from Italy, 3 from Germany; 2 from India, Iran, China, Taiwan and Turkey; and 1 case from each of UK, Israel, Bangladesh, and KSA.

The median age of patients was 44 years (24–78 years), while the median duration between vaccination and onset of clinical symptoms was 9 days (1–30 days). In 23/32 patients (71.8%), the onset of neurological symptoms followed the first dose of the vaccine, while only 9/32 (28.1%) developed the symptoms after the second dose.

During their current illness, a negative nasopharyngeal swab for SARS-CoV-2-RT-PCR was reported in 13/32 cases (40.6%). Meanwhile, 3 cases reported no previous history of COVID-19 infection, while the data was missing for the remaining cases.

Interestingly, 17/32 (53.1%) had history of a previously diagnosed immune-mediated condition; 7 patients had MS, one had CIS suggestive of MS (Patient 28), 2 had a history of recurrent neurological symptoms; one was diagnosed as MS in the current illness (Patient 19), while the other was diagnosed as TM (Patient 12), 3 reported a history of thyroid dysfunction (Hashimoto's thyroiditis in Patient 1 and hypothyroidism in

Patient 16 and Patient 20), 1 (Patient 3) had post-infectious rhombencephalitis, 1 (Patient 7) had atopic dermatitis, 1 had sarcoidosis (Patient 14), and 1 had Sjogren's disease (Patient 32).

In addition, one patient (Patient 18) reported a family history of MS, one had a history of cancer breast (Patient 10) and one had a history of cervical cancer (Patient 16).

A summary of the clinical characteristics is presented in [Table 1](#).

3.2. Clinical, laboratory and radiological data

When looking at the clinical pictures, the most common presentations were transverse myelitis (12/32), and MS- like (first diagnosis or relapse) pictures (12/32), followed by ADEM- like (5/32), and NMOSD- like (3/18) presentations.

Transverse myelitis presentation was reported in 12 patients, 6 males and 6 females, with a median age of 44.5 years (36–78 years). There was a median interval of 6.5 days (1–21) between receiving the vaccine and onset of symptoms. CSF analysis in this group showed pleocytosis in 6/12 patients with a median of 15 cells (6–481 cells/ μ L). Lymphocytes were the predominant cells in 4/6, while polymorphonuclear cells predominated in 2 patients. In addition, high protein level was reported in 8/12 cases, with a median of 0.596 g/L (0.44–1.68 g/L).

On spinal MRIs, simultaneous thoracic and cervical spinal cord involvement was reported in 6/12 cases, followed by isolated thoracic cord affection in 5/12 patients. On the other hand, isolated cervical cord

Table 1

Characteristics of cases presenting with CNS demyelination in relation to COVID-19 vaccines (Alshararni, 2021; Cao et al., 2021; Chen et al., 2021; Erdem et al., 2021; Etemadifar et al., 2021; Fitzsimmons and Nance, 2021; Gao et al., 2021; Havla et al., 2021; Helmchen et al., 2021; Hsiao et al., 2021; Khan et al., 2021; Khayat-Khoei et al., 2021; Maniscalco et al., 2021; Mathew and John, 2021; Malhotra et al., 2021; McLean and Trefts, 2021; Notghi et al., 2021; Ozgen Kenangil et al., 2021; Pagenkopf and Südmeyer, 2021; Raknuzzaman et al., 2021; Rinaldi et al., 2021; Seyed Ahadi et al., 2021; Tahir et al., 2021; Vegezzi et al., 2021; Vogrig et al., 2021; Watad et al., 2021).

Author	Age/Gender	Comorbidities	COVID-19 infection	Name of vaccine/Manufacturer	Vaccine type	Dose	Time relation between vaccine and symptoms	CNS demyelination type	Clinical picture	Laboratory investigations	CSF	MRI	Treatment	Outcome
1- Kenangil et al. ³²	46/F	Hashimoto's thyroiditis. Smoker.	Negative nasopharyngeal swab for SARS-CoV-2-RT-PCR	<i>Sinovac</i> 4 µg (Vero Cells, Beijing Institute of Biological Products Co., Ltd., Beijing, China)	Inactivated vaccine	2 nd	30 days	ADEM-like	First GTCs.	Positive: ANA and Anti-SOX1 Abs Negative : anti-dsDNA. Negative : AQP4 MOG Abs in serum.	Routine: normal. OCBs: negative.	Brain MRI: Multiple T2 and FLAIR hyperintense lesions in the LF thalamus, bilateral corona radiata, LF diencephalon, and RT parietal cortex. Some showing mild restricted diffusion on DWI, No enhancement.	IVMP 1 g/day for 7 days. Levothyroxine.	Stable. No seizures recurrence
2- Cao et al. ³³	24/F	None.	Negative nasopharyngeal swab for SARS-CoV-2-RT-PCR	<i>Sinovac</i> 4 µg (Vero Cells, Beijing Institute of Biological Products Co., Ltd., Beijing, China).	Inactivated vaccine	1 st	14 days	ADEM	Memory decline, headache, low-grade fever, muscle stiffness, extremity weakness, and reduced appetite. GTCs after 1 week.	Positive: SARS-CoV-2 IgG. Negative : AQP4, MOG, and anti-GFAP. Negative : autoimmune encephalitis, and paraneoplastic syndromes panels. Negative for HIV, and vasculitis.	Routine: WBC count of 25 × 106/L. Negative for antibodies to major pathogens and cultures of bacteria and fungi. Negative for OCBs.	Brain MRI: Abnormal signals in the bilateral temporal cortex. Repeat brain MRI on day 10 showed increased number of lesions. Complete resolution after 1 month.	IV ceftriaxone 2 g/day for 12 days and acyclovir 1.5 g/day for 16 days. IV diazepam, oral levetiracetam 1 g/day. IVIg 20 g/day for 5 days	Marked improvement. No seizures.

5- Rinaldi et al. ³⁶	45/M	None	NA	ChAdOx1 nCoV-19 Corona virus vaccine	Viral vector	1 st	12 days	ADEM	Numbness of all the upper limbs, trunk, and legs and progressive reduced visual acuity, dysarthria, dysphagia, clumsy right-hand movements, and urge incontinence.	Normal: Blood count, ESR, and CRP. Negative : infectious serum screening for HSV, HIV, Mycoplasma pneumoniae, and Borrelia burgdorferi. Negative : AQP4, MOG antibodies Negative : ANA, anticardiolipin antibodies	Routine: mild lymphocytosis (44 leucocytes, 98% mononuclear cells). Normal: protein, cytology, and no bacterial or viral infection. Negative: OCBs	Brain MRI: large, poorly margined T2-weighted hyperintensities in the pons, right cerebellar peduncle, right thalamus, and multiple spinal cord segments (at the cervical, dorsal, and conus medullaris level). All lesions, except the thalamic one and a single dorsal spinal area, showed blurred gadolinium enhancement on T1-weighted images	IVMP 1 g/day for 5 days followed by oral prednisolone.	Complete recovery.
6- Malhotra et al. ³⁷	36/M	None	NA	Recombinant ChAdOX1 nCoV-19 (Oxford/AstraZeneca, COVISHIELD TM) vaccine.	Viral vector	1 st	8 days	TM	Abnormal sensations in both lower limbs, ascending to the trunk.	Negative : AQP4 and MOG Abs. Negative : Abs for vasculitis and connective tissue disorders	Routine: Increased protein (54 mg%), normal for other parameters. Normal panel for infection screening.	Cervical spine MRI: Ovoid T2-hyperintense lesion in the dorsal aspect of spinal cord at C6 and C7 vertebral levels, showed mild to moderate peripheral enhancement. Brain MRI: normal.	Oral methylprednisolone (16 mg; 12 hourly) for a week. IVMP 1 g/day for five days.	Improvement.

7- Pagenko pf et al. ³⁸	45/M	Atopic dermatitis.	Negative nasopharyngeal swab for SARS-CoV-2-RT-PCR, no previous history of infection.	AstraZeneca (AZD1222)	Viral vector	1 st	11 days	TM (LETM)	Chills, headache, thoracic and back pain, and generalized weakness.	Negative : vasculitis profile, anti-neuronal Abs, and connective tissue diseases Abs. Negative : AQP4 and MOG-Abs in serum and CSF. Positive: SARS-CoV-2-IgG antibody.	Routine: Predominantly polymorphonuclear pleocytosis (481 cells/ μ l), increased protein (1.4 g/l), and decreased glucose (CSF/serum ratio 0.43). Negative: IgG index and OCB. Negative: RT-PCR for SARS-CoV-2-RNA and SARS-CoV-2 Abs.	Spinal MRI: LETM lesion showing T2 hyperintense signal of the spinal cord from C3 to Th2 without gadolinium enhancement. Brain MRI: was normal.	Acyclovir, ceftriaxone and ampicillin . IVMP 1 g/day for five days, followed by oral tapering.	Marked improvement.
8- Fitzsimmons et al. ³⁹	36/M	None	Negative nasopharyngeal swab for SARS-CoV-2-RT-PCR.	Moderna (Lot 036A21A)	mRNA-based vaccine	2 nd	1 day	TM	Lower limb numbness, low back pain, paresthesia, involuntary erection, urination, and constipation.	Normal: CBC, ESR, CRP and biochemistry profile. Negative: autoantibodies (AQP4, MOG). Positive: SSA Abs.	Routine: normal (Glucose:74 , Protein: 37, cells:3) Negative: autoantibodies (AQP4, MOG). Positive: SSA Abs.	Thoracic spinal MRI: Increased T2 cord signal in the distal spinal cord and conus with associated enhancement. Brain MRI: few non-specific hyperintensities, with no enhancement or restriction . Cervical and lumbar spinal MRI: Normal.	IVIg 0.5 g/kg. IVMP 1 g/day for 5 days, followed by oral prednisone.	Improvement.
9- Tahir et al. ⁴⁰	44/F	None	Negative SARS-CoV-2 nucleic acid amplification test.	Johnson and Johnson COVID-19 vaccine	Viral vector (non-replicating)	1 st	10 days	TM	Low-grade fever, chills, body aches, back pain, nausea, urinary retention, numbness and weakness in both lower extremities. Bell's palsy during PLEX therapy.	Normal CBC, and metabolic profile. Negative: AQP4 antibody. MBP (2.8 mcg/L), IgG index (0.67). Positive: OCBs.	Routine: WBCs (227 μ /L, 96% of lymphocytes), glucose (71 mg/dL), protein (43 mg/dL). Normal: workup for bacterial, viral, and fungal infection. Negative: AQP4 antibody. MBP (2.8 mcg/L), IgG index (0.67). Positive: OCBs.	Spinal MRI: Increased signal throughout the spinal cord extending from the C2-3 segment into the upper thoracic spine. Brain MRI: with and without contrast, was normal	High-dose methylprednisolone therapy for three days. PLEX for 5 treatments over 10 days after pulse therapy.	Improvement.

10- Erdem et al. ⁴¹	78/F	HTN. DM. Breast cancer.	Negative nasopharyngeal swab for SARS-CoV-2-RT-PCR.	Corona VAC vaccine (Sinovac Life Sciences, China).	Inactivated vaccine	2 nd	21 days	TM (LETM)	Tetra paresis, paresthesia of bilateral upper extremities, and urinary retention	Negative : vasculitis , infections, and malignancy profiles. Negative : AQP4 and MOG Abs.	Routine: Normal cell count, elevated protein level (56 mg/dL), normal glucose. Negative: OCB, and IgG index	Spinal MRI: LETM from the C1 to the T3 spinal cord segment. Brain MRI: normal	IVMP 1 g/day for 4 days, followed by PLEX.	Improvement.
11- Veggezzi et al. ⁴²	44/F	None	Negative nasopharyngeal swab for SARS-CoV-2-RT-PCR.	ChAdOx1 nCoV-19 vaccine (Batch ABV2856)	Viral vector	1 st	4 days	TM	Bilateral ascending paresthesia over 3 days. Reduced sensation in lower back and during micturition.	Negative : AQP4 and MOG Abs. Negative : anti-neuronal surface and onconeural Abs. Negative : SARS-CoV-2 IgG Abs.	Routine: Mildly elevated protein (76.7 mg/dl), lymphomonocytes (6/mm ³), undetectable lactate Negative: OCBs and IgG index.	Spinal MRI: Two lesions, in the posterior paramedian cord at D7-D8 level and in the LF lateral cord at D10-D11 level, with mild and patchy enhancement. Brain MRI: normal.	IVMP 1 g/day for 5 days, followed by oral tapering starting from 1 mg/kg/day.	Significant improvement. Followed by complete recovery.
12- Alsharani et al. ⁴³	38/M	Recurrent attacks of lower limb numbness and weakness	NA	Pfizer-BioNTech COVID-19	mRNA-based vaccine	1 st	2 days	TM	Headache, pain and weaknesses of lower extremities.	Normal routine analysis.	Routine: Elevated protein (621 mcg/L), normal glucose.	Spinal MRI: expanded edematous, faint, enhancing lesion at D11 and D12.	NA	NA
13- Khan et al. ⁴⁴	67/F	IHD CKD	NA	Moderna (Lot 036A21A)	mRNA-based vaccine	1 st	1 day	TM (LETM)	Bilateral upper and lower extremity weakness right more than left	Anemia: 8.5 g/dL Negative : MOG and AQP4 autoantibodies Negative : ANA, p-ANCA, and c-ANCA	Routine: Normal Negative OCBs IgG index 0.48.	Brain MRI: Scattered patchy foci (non-specific) Cervical spine MRI: hyperintense lesions in the upper cervical spine and cord edema extending from C1-C3 with patchy post-contrast enhancement.	IVMP 1 g/day for 3 days, followed by PLEX	Improvement.

14- Notghi et al. ⁴⁵	58/M	Sarcoidosis DM	NA	AstraZeneca COVID-19 vaccine	Viral vector	1 st	7 days	TM (LETM)	Progressive numbness in his lower limbs over 3 days, allodynia up to chest level, genital dysesthesia, and an episode of urinary incontinence.	Normal	Routine: elevated protein (1.68 g/L), lymphocytic pleocytosis Negative: OCBs	Whole spinal MRI: LETM from T2-T10 Prominent flow voids in the spinal canal at T9 level raised suspicion of DAVF. GAD: two separate foci of enhancing myelitis opposite T3-T4 and T9-T10 Follow up: More extensive hyperintense signal abnormality up to C1 level	IVMP 1 g/day for 5 days, followed by oral taper for 10 days. PLEX	Marked improvement.
15- Hsiao et al. ⁴⁶	41/M	DM	Negative nasopharyngeal swab for SARS-CoV-2-RT-PCR.	ChAdOx1 nCoV-19 vaccine (AZD1222)	Viral vector	1 st	7 days	TM (LETM)	Tingling sensation over T4 dermatome, followed by progressive paresthesia below T4, along with lower-limb weakness and clumsiness	Normal: CBC, metabolic profile. Negative paraneoplastic and autoimmune profiles. Negative: AQP4 antibodies	Routine: mild pleocytosis (WBC:11/uL) with predominant lymphocytes 100%) Mild elevated protein levels (44.3 mg/dL). Negative: for bacterial or viral CNS infection.	Spinal MRI: an intramedullary-enhancing lesion at T1 to T6 vertebral levels. Brain MRI: normal	IVMP 1 g/day for 5 days followed by oral taper.	Marked improvement.
16- McLean et al. ⁴⁷	69/F	Cervical cancer. Hypothyroidism. Restless leg syndrome	NA	Pfizer-BioNTech	mRNA-based vaccine	1 st	2 days	TM (LETM)	Lower extremity weakness and paresthesia extended to her hands bilaterally, incontinence, and incoordination.	Normal: routine, metabolic, vasculitis, and paraneoplastic profiles. Negative virology screening. Negative AQP4 and MOG autoantibodies	Routine: Normal cell count, protein, and glucose. Negative: VDRL, HSV, and Lyme. Negative: OCBs.	Brain MRI: Normal Spinal MRI: extensive T2 signal abnormalities seen particularly in the anterior aspect, as well as the mid-cord extending from C3-4 down to T2-3	IVMP 1 g/day for 5 days.	Partial improvement.

17- Gao et al. ⁴⁸	76/F	Vitamin B12 deficiency.	NA	Moderna (mRNA-1273)	mRNA-based vaccine	1 st	6 days	TM (LETM)	Unsteadiness and abnormal sensation in the limbs, predominantly on the right side, and sacral paresthesia	Negative: RF, and ANA Negative: AQP4 antibodies	Routine: mild pleocytosis (15/ μ L) with neutrophil predominance (73%) and increased protein levels (57.2 mg/dL) Negative: CNS infection.	Brain MRI: Normal Cervical spinal MRI: Extensive intramedullary hyperintensity in the cervical cord at the C2–C5 levels on T2-weighted images, and at the C3 level with T1 ring enhancement.	IVMP 1 g/day for 5 days followed by oral prednisolone.	Marked improvement.
18- Havla et al. ⁴⁹	28/F	Family history was positive for MS	Negative nasopharyngeal swab for SARS-CoV-2-RT-PCR.	Pfizer-BioNTech COVID-19 vaccine (BNT162b2, Comirnaty [®] , BioNTech/Pfizer)	mRNA-based vaccine	1 st	6 days	MS	Left abdominal neuropathic pain, left leg paresis.	SARS-CoV-2 S Abs (IgG) were detected in serum (50.8 U/ml, 37 days after vaccination).	Routine: Mild pleocytosis (7 cells/ μ L). Positive: OCBs.	Spinal MRI: Contrast-enhancing lesion at T6 level. Brain MRI: multiple (> 20), partially confluent lesions with spatial dissemination but without enhancement.	IVMP 1 g/day for 5 days, followed by a second cycle of IVMP 2 g/day for 5 days. PLEX	Partial improvement.
19- Mathew et al. ⁵⁰	24/F	Two episodes of neurological dysfunction four years apart (Dissemination in time)	NA	ChAdOx1 nCoV-19 Corona virus vaccine	Viral vector	2 nd	7 days	MS	Paresthesia of left upper and lower limbs, positive Lhermitte's phenomena	NA	NA	Brain and spinal MRIs: two lesions in the brain and one lesion in the spinal cord with enhancement.	IVMP 1 g/day for 5 days, followed by oral steroids at 60 mg/day.	Marked improvement.
20- Wataid et al. ⁵¹	45/F	Hypothyroidism.	No	Pfizer-BioNTech COVID-19 vaccine (BNT162b2) vaccine	mRNA-based vaccine	1 st	7 days	MS	Left leg weakness, disequilibrium, and lower limbs distal numbness	Normal: CBC and biochemistry.	Positive: OCBs.	Brain MRI: multiple PV white matter changes.	IVMP 1 g daily for 5 days, then prednisone 60 mg daily with tapering dose.	Marked improvement.

21- Etemadifar et al. ⁵²	34/F	RRMS (for 13 years, on rituximab, last infusion 3 months)	No previous history of infection.	Gam-COVID-Vac (Sputnik V) COVID-19 vaccine	Viral vector	1 st	3 days	MS relapse	Fatigue, myalgia, generalized weakness, progressed to severe right hemiplegia and ataxia	Normal: routine investigations. Normal: serum anti-SARS-CoV-2 IgG and IgM after 21 days.	Not done.	Brain MRI: several new PV, juxtacortical, brainstem, and cerebellar peduncle lesions. No Gd enhancement.	IVMP 1 g/day for 5 days, followed by oral steroids.	Marked improvement.
22- Maniscalco et al. ⁵³	26/F	RRMS (for 5 years, on cladribine)	NA	BNT162b2 COVID-19 vaccine	mRNA-based vaccine	1 st	2 days	MS relapse	Paresthesia in her left arm followed by weakness in her left upper and lower limbs.	WBCs, levels of CD3,4,8, 19,20 were normal before and after vaccine.	NA	Brain MRI: voluminous enhancing lesions in frontal temporal cortices.	IVMP 1 g/day for 5 days.	Complete recovery.
23- Khayat-Khoei et al. ⁵⁴	35/F	RRMS (for 11 years on Natalizumab)	NA	Moderna (mRNA-1273)	mRNA-based vaccine	2 nd	21 days	MS relapse	Right arm, dysmetria, impaired balance/gait	Negative: Serum JC virus and natalizumab neutralizing antibodies.	Not done	Brain MRI: a new T2 hyperintense lesion in the right cerebellum that enhanced with gadolinium	IVMP 1 g/day for 5 days	Complete recovery.
24- Khayat-Khoei et al. ⁵⁴	26/F	None	Negative nasopharyngeal swab for SARS-CoV-2-RT-PCR.	Moderna (mRNA-1273)	mRNA-based vaccine	2 nd	14 days	MS	Progressive blurred vision and pain of left eye	Negative: ANA, C-ANCA and Lyme titer	Routine: elevated cell count. Elevated IgG index (CSF/serum at 1.27). Negative OCBs.	Brain MRI: multiple T2 hyperintense periventricular, subcortical, posterior fossa, and spinal cord lesions. Two of the lesions enhanced after GAD administration.	IVMP 1 g/day for 5 days	Complete recovery.
25- Khayat-Khoei et al. ⁵⁴	24/F	RRMS (for 9 years on fingolimod)	Negative nasopharyngeal swab for SARS-CoV-2-RT-PCR.	Pfizer-BioNTech (BNT162b2)	mRNA-based vaccine	2 nd	1 day	MS relapse	Vision changes and pain of left eye	Positive serum SARS-CoV-2 spike antibody	Not done	Brain and Orbit MRI: several new enhancing brain lesions without any optic abnormalities	IVMP 1 g/day for 3 days	Complete recovery.

26- Khayat- Khoei et al. ⁵⁴	33/M	None	NA	Pfizer- BioNTech (BNT162b2)	mRN A- based vaccin e	2 nd	1 day	MS	Unilateral painless blurring of vision	Negative : AQP4 antibody.	Routine: Normal Positive OCBs, with elevated IgG index.	MRI Brain: Multiple T2 hyperinte nse white matter lesions with a single gadolinium- enhancing lesion.	IVMP 1 g/day for 3 days	Complete recovery.
27- Khayat- Khoei et al. ⁵⁴	44/F	RRMS (for 24 years, no treatment)	NA	Moderna (mRNA- 1273)	mRN A- based vaccin e	2 nd	6 day s	MS relapse	Ascending numbness, right sided weakness.	NA	Not done	Brain MRI: new enhancing lesion in the brain	IVMP 1 g/day for 3 days	Complete recovery.
28- Khayat- Khoei et al. ⁵⁴	48/F	CIS (for 8 years, was on glatiramer acetate)	NA	Pfizer- BioNTech (BNT162b2)	mRN A- based vaccin e	1 st	15 da ys	MS	Pain with right eye movement, worsened Lhermitte's, and balance/gait difficulty	NA	Not done	MRI Brain: Three new T2 hyperinte nse white matter lesions.	Oral methylpre dnisolone (1000 mg daily).	Marked improvement.
29- Ahadi et al. ⁵⁵	42/F	RRMS (for 20 years, not on treatment)	NA	Sinopharm vaccine (BBIBP- CorV's Beijing Institute of Biological Products)	Inactiv ated vaccin e	1 st	2 days	MS relapse	Progressive paraparesis without paresthesia	Normal: ESR, CRP, CBC, and urine analysis and culture.	Not done	MRI Brain and cervical spine: periventricu lar, anterior temporal, cerebellar and anterior medullary white matter hyper- intensities Nodular enhancem ent in brainstem plaque.	IVMP 1 g/day for 5 days	Improvement.
30- Helmche n et al. ⁵⁶	40/F	RRMS (for 21 years, on natalizuma b)	Negative nasophar yngal swab for SARS- CoV-2- RT-PCR.	Astra Zeneca, COVID19 Vaccine®; Vaxzevria®)	Viral vector	1 st	14 days	NMOSD -like relapse (ON/LE TM)	Paraplegia, loss of sensory function below T5, and incontinence , rapidly progressing binocular blindness, back pain, and inability to walk.	Negative : MOG, GFAP, AQP4 in serum and CSF. Negative : virus antigens, vasculitis , and infection profiles. Negative : MRZ reaction, NAT and JC virus antibodie s.	Routine: Severe pleocytosis (524 leucocytes/ µl, 98% neutrophil granulocyte s), increased lactate (6.6 mmol/l) and strongly elevated protein (2.2 g/l).	Brain MRI: numerous old WM lesions compatibl e with MS. Increased signal intensity in the chiasm and optic nerves and tracts, with mild chiasm enhancem ent. Spinal MRI: LETM at TH7-10, and in the conus , and other lesions in C4/C5.	IVMP 2 g/day for 5 days, followed by PLEX, and immunoa d sorption.	Improved visual acuity but unchanged paraplegia.

31- Chen et al. ⁵⁷	Middle-aged/F	None	NA	Probable Sinovac or Sinopharm vaccine (China)	Inactivated vaccine	1 st	3 days	NMOSD	Fever, vomiting, diarrhea, cough, dizziness, and unsteady gait.	Leucopenia (2.36 × 10 ⁹ /L), and Positive: AQP4, ANA, SSA, SSB, Ro-52, and p-ANCA Abs.	Routine: WBCs 31 × 10 ⁶ /L, all mononuclear cells, normal glucose, and protein. Negative: OCBs.	Brain MRI: area postrema and bilateral hypothalamus lesions without Gd enhancement. Orbit and spinal MRIs: normal.	IVMP 500 mg/day for 5 days.	Marked improvement.
32- Khayat-Khoie et al. ⁵⁴	64/M	Sjogren's disease	Negative nasopharyngeal swab for SARS-CoV-2-RT-PCR.	Pfizer-BioNTech (BNT162b2)	mRNA-based vaccine	1 st	18 days	NMOSD (LETM)	Pain, paresthesia, urinary retention, constipation, impaired balance/gait	Positive: AQP4 and SS-A/SS-B antibodies	Routine: Normal Positive: AQP4 antibodies. Negative: OCBs and IgG index.	MRI spinal cord: minimally expansile central spinal cord T2 hyperintensity extending from the cervical cord to the conus, with patchy areas of gadolinium enhancement. MRI Brain: Demyelinating lesions.	IVMP 1 g/day for 3 days, PLEX.	Partial recovery.

COVID-19: Coronavirus disease 2019, SARS-CoV-2: severe acute respiratory syndrome- related coronavirus 2, RT-PCR: reverse transcriptase polymerase chain reaction, NP: nasopharyngeal, Abs: antibodies, Q.D: quarter in die (four times a day), GTCs: Generalized tonic-clonic convulsions, ANA: antinuclear antibody, SOX-1: SRY-BOX Transcription Factor 1, AQP4: aquaporin 4, MOG: myelin oligodendrocyte glycoprotein, LF: left, RT: right, CSF: cerebrospinal fluid, HIV: human immunodeficiency virus, IV: intravenous, IgG: immunoglobulin G, MRI: magnetic resonance imaging, FLAIR: fluid attenuated inversion recovery, DW: diffusion weighted, mRNA: messenger ribonucleic acid, IVMP: intravenous methyl prednisolone, TM: transverse myelitis, LETM: longitudinally extensive transverse myelitis, OCBs: oligoclonal bands, ADEM: acute disseminated encephalomyelitis, Anti- ds DNA: anti- double stranded DNA, MMSE: Mini-Mental State Examination, GFAP: glial fibrillary acidic protein, MS: multiple sclerosis, WM: white matter, IVIG: intravenous immunoglobulins, GCS: Glasgow coma scale, ESR: erythrocyte sedimentation rate, NMOSD: neuromyelitis optica spectrum disorder, PLEX: plasma exchange, CBC: complete blood count, ESR: erythrocyte sedimentation rate, CRP: C-reactive protein, p-ANCA: WBC: white blood count, OCBs: oligoclonal bands, IgG index: immunoglobulin G, PV: periventricular, GFAP: glial fibrillary acidic protein, MRZ: measles, rubella, zoster, CIS: clinically isolated syndrome, DAVF: dural arteriovenous fistulae, IHD: ischemic heart disease.

was noted in 2 patients, while conus medullaris involvement was reported in only one patient. Longitudinally extensive transverse myelitis (LETM) was the main radiological feature in 7/12 patients, while short segment involvement was reported in 5/12. In patient 8, conus pathology was part of a lesion involving the thoracic cord, however, serological testing for AQP4 and MOG antibodies was negative. Brain MRI was abnormal in only two of the myelitis patients with non-specific hyperintensities showing neither restriction nor contrast enhancement.

MS-like presentation was reported in 12 patients, of which, 6 had a well-established diagnosis of MS prior to vaccination, and the vaccine was hypothesized to have triggered a relapse, while 4 patients experienced their first episode post-vaccination. Additionally, one patient had a history of previous episodes of neurologic dysfunction without receiving a diagnosis of MS (Patient 19) and one patient (Patient 28) was diagnosed as CIS suggestive of MS. Eleven were females as opposed to only one male. Their median age was 33.5 years (24–48 years). The

median interval between vaccination and symptoms development was 6 days (1–21 days). Half of the patients (6/12) developed their symptoms after the 1st dose of vaccination. Brain MRI depicted demyelinating lesions in all patients (12/12), while spinal cord involvement was reported in (3/12) patients (Patients 18, 19 and 24), was unremarkable in one (Patient 29) and not assessed in the rest. The diagnosis of MS was supported by positive oligoclonal bands (OCBs) in 3/12 patients (Patients 18, 20 and 26).

ADEM-like presentation was reported in 5 patients (3 females, 2 males), with a median age of 46 years (24–56 years). The time interval to symptom development was longer than other presentations, with a median of 14 days (12–30 days).

Generalized tonic-clonic seizures (GTCS) were reported in 3/5 patients, while confusion and headache were seen in 2/5 patients. Serological testing for AQP4 and MOG antibodies was negative in 4 patients and was not tested in the fifth. CSF analysis showed pleocytosis in 3/5 patients (Patient 2, 4 and 5), while elevated protein was reported in only

one patient (0.75 g/L). Moreover, OCBs were tested in 4/5 patients and were negative.

All reported MRI lesions were supratentorial. Some lesions showed contrast enhancement (Patient 5). Additionally, spinal cord was involved in the form of multifocal lesions in one case (Patient 5).

NMOSD-like presentation was reported in 3 cases. One of them (Patient 30) was previously diagnosed with MS, and was on natalizumab for 21 years, when she suffered simultaneous optic neuritis and LETM. Even though she tested negative for AQP4 antibody in serum and CSF, her imaging features were more in favor of NMOSD rather than MS. Moreover, her CSF showed severe pleocytosis (542 cells/ μ l) with neutrophils predominance and markedly elevated protein (2.2 g/L). Unfortunately, testing for MOG antibody and OCBs in CSF was not reported. The other patient (Patient 31) presented by the characteristic area postrema syndrome that was supported by MRI data and positive serology for AQP4 antibodies. CSF analysis had elevated white blood cells count of (31 cells/ μ l), with mononuclear cells as the predominant type. The third patient (Patient 32) was a 64-year-old male with a history of Sjogren's disease. His presentation suggested spinal cord involvement which was supported radiologically by extensive cord involvement from cervical region to conus. Serological testing was positive for AQP4 antibodies. Brain MRI showed demyelinating patches as well.

3.3. Treatment and outcome

When addressing the management plans, treatment comprised high dose methylprednisolone (with or without oral tapering), PLEX, IVIG, or a combination of those. Antiviral/ antibiotics were also given in few cases. Fortunately, interventions achieved either marked/complete improvement in 25/32 (78.1%) cases, stabilized or resulted in partial recovery in the rest.

Finally, to further characterize the cases, we classified them based on the received vaccine type (Table 2). CNS demyelination was reported after all types of vaccines in the literature. The mRNA-based vaccines resulted in the greatest number of demyelinating syndromes (17/32), followed by viral vector vaccines (10/32) as opposed to 5 cases following inactivated vaccines. Similarly, most MS-like episodes (9/12) were triggered by mRNA-based vaccines.

However, in TM cases, viral vector vaccines were associated with demyelination in 6/12 cases, followed by mRNA-based vaccines (5/12), and only one case following inactivated vaccines. Furthermore, the median interval between receiving inactivated COVID-19 vaccines and symptom development was longer; 14 days, as opposed to 7.5 and 6 days for viral vector and mRNA vaccines, respectively.

Data regarding the second dose of vaccination, for those who developed symptoms after the first dose, was available for only 9/23 cases; 4 cases did not adhere to the vaccination schedule, 3 cases switched from viral vector to an mRNA vaccine, and 2 cases received the second dose without any new symptoms.

4. Discussion

Since the early 1800s, vaccines have been the most efficient solution in preventing viral infections. However, in rare occasions, vaccines induced unexpected inflammatory reactions, or has been associated with manifest autoimmune diseases, within a short period of time following their administration (Lu et al., 2021b).

In order to be defined as vaccine-induced, the WHO had suggested certain criteria to be met (Wraith et al., 2003), including: (1) temporal relationship (vaccination must precede the occurrence of the event), (2) consistency of evidence (similar or same results generated by studies using different methods in different settings), (3) strength of association (statistical significance to demonstrate that it was not a chance occurrence), (4) specificity (vaccine is the only cause of the event), and (5) biological plausibility and coherence (there must be a biologically plausible mechanism between cause and effect). Such strict criteria were rarely met in the majority of cases in the literature, similar to our review, making inference of causation a challenge. In literature, few post-vaccination autoimmune diseases were firmly and reliably considered as vaccine-associated, such as GBS cases following 1976 swine influenza vaccine. However, other suspected associations, such as the hepatitis B vaccine and MS, and HPV vaccine and ADEM, have not been strongly confirmed (Salemi and D'Amelio, 2010).

A PubMed search from 1979 to 2013 by Karussis and colleagues (Karussis and Petrou, 2014a), revealed 71 documented cases of post-vaccination CNS demyelination. The most reported vaccines were influenza, HPV, and hepatitis A or B vaccines. Symptoms usually appeared within 2 weeks (mean: 14.2 days), however, delayed presentation (4 weeks and up to 5 months post-vaccination) has been reported. The commonest clinical presentations were optic neuritis, multifocal disseminated demyelination, TM, and encephalitis. Furthermore, Agmon-Levin and colleagues (Agmon-Levin et al., 2009) reported only 37 cases, from 1970 to 2009, in association with several vaccines, including hepatitis B, measles-mumps-rubella, and diphtheria-tetanus-pertussis.

The concern of a potential association of CNS autoimmune inflammation and COVID-19 vaccines has been recently raised, as cases began to unfold. According to the interim analysis of four randomized controlled trials of ChAdOx1 nCoV-19 vaccine (AZD1222), 3 cases of ATM were reported, from 11, 636 participants included. One case was considered to be an idiopathic demyelination that is possibly related to the vaccine, while the other two were most likely a pre-existing or previously unrecognized MS (Voysey et al., 2021). However, in a recent review of 11 COVID-19 vaccine candidates (Lu et al., 2021a), the preliminary official data from the vaccine manufactures and the drug authorities suggested that neurologic adverse events were rare, and cases of CNS demyelination were reported in association with viral vector vaccine only.

In our review, CNS demyelination was reported following all types of approved COVID-19 vaccines (no protein-based vaccine was approved at the time of writing). Neurological symptoms appeared within the first 1–2 weeks in most cases. Females comprised the majority of cases, which agrees with data in literature, where around 85% of immune-mediated

Table 2
Classification of cases based on the received vaccine type.

Vaccine	Number of demyelination cases	Median age (years)	Median interval (days)	TM	ADEM-like	MS-like	NMOSD-like	Immune- mediate conditions
mRNA (Pfizer, Moderna)	17	44 (24–76)	6 (1–21)	5	2	9	1	10
Viral vector (Astra, Sputnik, J&J)	10	42.5 (24–58)	7.5 (3–14)	6	1	2	1	5
Inactivated (Sinopharm, Sinovac)	5	44 (24–78)	14 (2–30)	1	2	1	1	2

diseases affects women (Angum et al., 2020). This has been attributed to greater immune responses against foreign and self-antigens in women compared to men. Furthermore, more than half of the cases had history of probable or definite autoimmune diseases, which could make them liable to increased risk of developing other immune-mediated diseases (Somers et al., 2009).

The mRNA-based vaccines resulted in the greatest number of demyelinating syndromes (53.1%), followed by viral vector vaccines (31.2%), as opposed to (15.6%) following inactivated vaccines. Similarly, 75% of MS-like episodes were triggered by mRNA-based vaccines. However, it should be noted that more patients with immune-mediated diseases received mRNA-based vaccines compared to the other types combined (10 vs 7 cases, respectively). Furthermore, TM cases were associated with both viral vector and mRNA-based vaccines (50% vs 41.6%, respectively), contrary to earlier published data, which limited TM to viral vector vaccines only (Lu et al., 2021a).

As of September 2021, VAERS database had 328 reports of suspected cases of TM worldwide, following all types of vaccines. However, a recent analysis of VAERS data revealed no increased risk of neuro-autoimmune adverse events from COVID-19 vaccines compared to other vaccines (von Csefalvay, 2021).

At the time of writing, 6.4 billion doses of COVID-19 vaccines have been given, and 2.7 billion were fully vaccinated. Considering the annual incidence of TM of 1.34 to 4.60/ million in general population, 24.6/ million in cases of acquired demyelination (Beh et al., 2013), and 0.5/million in COVID-19 patients (Román et al., 2021), the current incidence of post-vaccination TM would be considered low.

Moreover, few cases of ADEM were reported, given that ADEM is the prototype and one of the most common white matter diseases associated with vaccines. ADEM is usually monophasic with a widely variable clinical presentation and favorable outcome, which was seen in our cases (Karussis and Petrou, 2014a).

Six MS patients had clinical relapses, while another 6 were newly diagnosed with MS following vaccination. Vaccines had long been incriminated in the development of MS, or in triggering MS relapses. However, pooled analysis from multiple studies found no sufficient evidence to support a causal relationship between the onset of MS and various common vaccinations (Farez and Correale, 2011). Moreover, a 2017 systematic review of more than 50 articles (Mailand and Frederiksen, 2017) found no increased risk in developing MS and in relapses after vaccination.

As regards to COVID-19, Achiron and colleagues (Achiron et al., 2021) found no increased risk of relapse activity in MS patients who received BNT162b2 vaccine as well. The relapse rate was higher following the first dose than the second dose (2.1% and 1.6%, respectively), which was similar to the rate in non-vaccinated patients during the corresponding period. However, in our review, MS relapse rate occurred following first and second doses equally. Moreover, they found that relapse rate was slightly higher in younger patients and in those treated with immunomodulatory drugs. However, their review was limited to cases who received BNT162b2 COVID-19 vaccine only, with a relatively short follow-up period.

Interestingly, NMOSD-like presentation was reported in 3 cases, raising the possibility of cross-reactivity between the used viral antigens and aquaporin-4. This predisposition to the spinal cord and the optic nerves has also been reported following other vaccines (e.g. HPV) vaccine (Karussis and Petrou, 2014b).

A favorable outcome was noted in the majority of the reported cases, which was similar to the findings of a recent nationwide study (García-Grimshaw et al., 2021), where most patients with neurological complications experienced complete recovery within days to weeks without long-term sequelae.

The exact mechanism of demyelination after COVID-19 vaccines remains poorly understood, however, it is postulated that a combination of vaccine-related factors, in addition to susceptibility of the patients, could be involved. Molecular mimicry represents one of the main

immunopathogenic factors, where similarity between the proteins of the viruses used for the vaccination and self-antigens (e.g. myelin) triggers an undesired immune-response (García-Grimshaw et al., 2021).

In ChAdOx1 vaccine (AZD1222); a SARS-CoV-2 structural surface vector glycoprotein antigen (spike protein; nCoV-19) gene is included in a replication-deficient chimpanzee adenovirus, which could be a possible trigger of demyelination (CDC, 2021; Knoll and Wonodi, 2021).

Another important factor is the pathogenic role of immunologic adjuvants (substances that are used to enhance the antigen-specific immune responses), which can mimic evolutionarily conserved molecules activating both the innate and adaptive immune systems (Vera-Lastra et al., 2013). The mRNA vaccine exhibits a property of self-adjuvantation, where the mRNA acts as both antigen and adjuvant. A theoretical risk of inducing an autoimmune reaction could be related to activation of toll-like receptors TLR7 and TLR8, resulting in type I interferon production, and eliciting robust T and B cell responses, thus activating bystander autoreactive lymphocytes (Velikova and Georgiev, 2021). This bystander activation, along with macrophages secreting cytokines, can result in local inflammation and the recruitment of additional T-helper cells (Aharon-Maor and Shoenfeld, 2000).

Other etiologies include vaccine-related factors such as the type, dose and the route of administration (Velikova and Georgiev, 2021), in addition to a possible immunological and genetic susceptibility of the patients.

Finally, in a recent review (Ismail and Salama, 2021), 102 cases of CNS demyelination were reported in association with COVID-19 infection, from January 1, 2020, until June 15, 2021, while only 32 cases in association with COVID-19 vaccine were reported in a 10-month period. This is in line with robust evidence in literature, which documents a substantially higher risk of demyelination following infections, compared to the different types of vaccines (García-Grimshaw et al., 2021; De Martino et al., 2013). Although non-negligible, COVID-19 vaccine-associated CNS demyelination is still relatively low, and the benefits of vaccinations surpass the potential risks of CNS inflammation.

4.1. Limitations

This systematic review has some limitations. Since all available literature were reported as single case reports and one case series so far, there could be some sort of reporting and/or publication bias. In addition, we presented the reports as a set of cases for practical reasons, however, one should be wary of interpreting the data as coming from a uniform cohort, and inferring direct causality from the anecdotal data provided. Moreover, the small number of reported cases, the heterogeneity of clinical data, or the incomplete work-up in some cases, hindered the ability to perform a meta-analysis. Despite these shortcomings, the current review represents the first preliminary data on the association of COVID-19 vaccination and CNS demyelination, which can help future research.

5. Conclusion

In this review, CNS demyelination occurred following all types of approved COVID-19 vaccines. Clinical presentation was heterogeneous, including TM, MS, ADEM and NMOSD. Symptoms occurred within 1–2 weeks, mainly following the first dose of vaccine. Interestingly, more than half of the reported cases had history of immune-mediated diseases. A favorable outcome was observed in the majority of cases after treatment. Currently, the world is facing the largest mass vaccination campaign in history, and cases of demyelination will inevitably occur, either directly following vaccination, or by chance. However, the incidence appears to be low, in comparison to demyelination following COVID-19 infection. Although association does not always imply causation, long-term post-marketing surveillance for cases of demyelination is warranted, to assess for causality, and ensure the safety of COVID-19 vaccines.

Funding

No funding received.

Declaration of Competing Interest

The authors declare that the research was conducted in the absence of any commercial or financial relationships that could be construed as a potential conflict of interest.

References

- Achiron, A., Dolev, M., Menascu, S., Zohar, D.-N., Dreyer-Alster, S., Miron, S., et al., 2021 May. COVID-19 vaccination in patients with multiple sclerosis: what we have learnt by February 2021. *Mult. Scler.* 27 (6), 864–870.
- Agmon-Levin, N., Kivity, S., Szyper-Kravitz, M., Shoenfeld, Y., 2009 Nov. Transverse myelitis and vaccines: a multi-analysis. *Lupus*. 18 (13), 1198–1204.
- Aharon-Maor, A., Shoenfeld, Y., 2000 Mar. The good, the bad and the ugly of vaccination. *Isr. Med. Assoc. J.* 2 (3), 225–227.
- Alshararni, Ali, 2021 Jul 26. Acute transverse Myelitis associated with COVID-19 vaccine: a case report. *IJRPS* 12 (3), 2083–2087.
- Angum, F., Khan, T., Kaler, J., Siddiqui, L., Hussain, A., 2020 May 13. The prevalence of autoimmune disorders in women: a narrative review. *Cureus* 12 (5), e8094. <https://doi.org/10.7759/cureus.8094> [Internet]. [cited 2021 Sep 2]; Available from: <https://www.cureus.com/articles/31952-the-prevalence-of-autoimmune-disorders-in-women-a-narrative-review> (PMID: 32542149; PMCID: PMC7292717).
- Beh, S.C., Greenberg, B.M., Frohman, T., Frohman, E.M., 2013 Feb. Transverse Myelitis. *Neurol. Clin.* 31 (1), 79–138.
- Cao, L., Ren, L., et al., 2021 Feb 1. *Acta Neurol. Belg.* <https://doi.org/10.1007/s13760-021-01608-2> [Internet]. [cited 2021 Sep 2]; Available from: CDC, 2021. Vaccine Adverse Event Reporting System (VAERS). US Department of Health and Human Services, CDC, Atlanta, GA. Accessed August 15, 2021.
- Chen, S., Fan, X.-R., He, S., Zhang, J.-W., Li, S.-J., 2021 Jun 29. Watch out for neuromyelitis optica spectrum disorder after inactivated virus vaccination for COVID-19. *Neurol. Sci.* <https://doi.org/10.1007/s10072-021-05427-4> [Internet]. [cited 2021 Sep 2]; Available from: von Csefalvay, C., 2021 Jun. VAERS data reveals no increased risk of neuroautoimmune adverse events from COVID-19 vaccines [Internet]. *Inf. Dis. (except HIV/AIDS)*. <https://doi.org/10.1101/2021.06.13.21258851> [cited 2021 Sep 2]. Available from: De Martino, M., Chiappini, E., Galli, L., 2013 Apr. Vaccines and autoimmunity. *Int. J. Immunopathol. Pharmacol.* 26 (2), 283–290.
- Erdem, N.Ş., Demirci, S., Özel, T., Mamadova, K., Karaali, K., Çelik, H.T., et al., 2021. Acute transverse myelitis after inactivated COVID-19 vaccine. *Idoggyogy Sz.* 74 (7–8), 273–276.
- Etemadifar, M., Sigari, A.A., Sedaghat, N., Salari, M., Nouri, H., 2021 May. Acute relapse and poor immunization following COVID-19 vaccination in a rituximab-treated multiple sclerosis patient. *Human Vacc. Immunotherap.* 20, 1–3.
- Farez, M.F., Correale, J., 2011 Jul. Immunizations and risk of multiple sclerosis: systematic review and meta-analysis. *J. Neurol.* 258 (7), 1197–1206.
- Fitzsimmons, W., Nance, C.S., 2021. Sudden Onset of Myelitis after COVID-19 Vaccination: An Under-Recognized Severe Rare Adverse Event. *SSRN J.* [Internet]. [cited 2021 Sep 2]; Available from: <https://www.ssrn.com/abstract=3841558>.
- Gao, J.-J., Tseng, H.-P., Lin, C.-L., Shiu, J.-S., Lee, M.-H., Liu, C.-H., 2021 Sep 10. Acute transverse myelitis following COVID-19 vaccination. *Vaccines*. 9 (9), 1008.
- García-Grimshaw, M., Ceballos-Liceaga, S.E., Hernández-Vanegas, L.E., Núñez, I., Hernández-Valdivia, N., Carrillo-García, D.A., et al., 2021. Systemic and Neurologic Adverse Events Among 704,003 First-Dose Recipients of the Pfizer-BioNTech (BNT162b2) mRNA COVID-19 Vaccine in Mexico. *SSRN J.* 229, 108786. <https://doi.org/10.1016/j.clim.2021.108786> [Internet]. [cited 2021 Sep 2]; Available from: <http://www.ssrn.com/abstract=3816489>.
- Goss, A.L., Samudralwar, R.D., Das, R.R., Nath, A., 2021 May. ANA investigates: neurological complications of COVID-19 vaccines. *Ann. Neurol.* 89 (5), 856–857.
- Havla J, Schultz Y, Zimmermann H, Hohlfeld R, Danek A, Kumpfel T. First manifestation of multiple sclerosis after immunization with the Pfizer-BioNTech COVID-19 vaccine. *J. Neurol.* [Internet]. 2021 Jun 11 [cited 2021 Sep 2]; Available from: doi: <https://doi.org/10.1007/s00415-021-10648-w>.
- Helmchen, C., Buttler, G.M., Markewitz, R., Hummel, K., Wiendl, H., Boppel, T., 2021 Jun 15. Acute bilateral optic/chiasm neuritis with longitudinal extensive transverse myelitis in longstanding stable multiple sclerosis following vector-based vaccination against the SARS-CoV-2. *J. Neurol.* <https://doi.org/10.1007/s00415-021-10647-x> [Internet]. [cited 2021 Sep 2]; Available from: Hernández, A.F., Calina, D., Poulas, K., Docea, A.O., Tsatsakis, A.M., 2021. Safety of COVID-19 vaccines administered in the EU: should we be concerned? *Toxicol. Rep.* 8, 871–879.
- Hsiao, Y.-T., Tsai, M.-J., Chen, Y.-H., Hsu, C.-F., 2021 Sep 25. Acute transverse myelitis after COVID-19 vaccination. *Medicina*. 57 (10), 1010.
- Ismail, I.I., Salama, S., 2021 Aug 12. Association of CNS demyelination and COVID-19 infection: an updated systematic review. *J. Neurol.* <https://doi.org/10.1007/s00415-021-10752-x> [Internet]. [cited 2021 Sep 2]; Available from: Karussis, D., Petrou, P., 2014 Mar. The spectrum of post-vaccination inflammatory CNS demyelinating syndromes. *Autoimmun. Rev.* 13 (3), 215–224.
- Karussis, D., Petrou, P., 2014 Mar. The spectrum of post-vaccination inflammatory CNS demyelinating syndromes. *Autoimmun. Rev.* 13 (3), 215–224.
- Khan, E., Shrestha, A.K., Colantonio, M.A., Liberio, R.N., Sriwastava, S., 2021 Sep 5. Acute transverse myelitis following SARS-CoV-2 vaccination: a case report and review of literature. *J. Neurol.* <https://doi.org/10.1007/s00415-021-10785-2> [Internet]. [cited 2021 Oct 11]; Available from: Khayat-Khoei, M., Bhattacharyya, S., Katz, J., Harrison, D., Tauhid, S., Brusio, P., et al., 2021 Sep 4. COVID-19 mRNA vaccination leading to CNS inflammation: a case series. *J. Neurol.* 1–14.
- Knoll, M.D., Wonodi, C., 2021 Jan. Oxford–AstraZeneca COVID-19 vaccine efficacy. *Lancet* 397 (10269), 72–74.
- Ling, Y., Zhong, J., Luo, J., 2021 Jul 26. Safety and effectiveness of SARS-CoV-2 vaccines: A systematic review and meta-analysis. *J. Med. Virol.* 93 (12), 6486–6495. <https://doi.org/10.1002/jmv.27203> PMID: 34264528; PMCID: PMC8426880.
- Lu, L., Xiong, W., Mu, J., Zhang, Q., Zhang, H., Zou, L., et al., 2021 Jul. The potential neurological effect of the COVID-19 vaccines: a review. *Acta Neurol. Scand.* 144 (1), 3–12.
- Lu, L., Xiong, W., Mu, J., Zhang, Q., Zhang, H., Zou, L., et al., 2021 Jul. Neurological side effects of COVID-19 vaccines are rare. *Acta Neurol. Scand.* 144 (1), 111–112.
- Mahase, E., 2020 Sep. Covid-19: Oxford researchers halt vaccine trial while adverse reaction is investigated. *BMJ*. 9, m3525.
- Mailand, M.T., Frederiksen, J.L., 2017 Jun. Vaccines and multiple sclerosis: a systematic review. *J. Neurol.* 264 (6), 1035–1050.
- Malhotra, H.S., Gupta, P., Prabhu, V., Kumar Garg, R., Dandu, H., Agarwal, V., 2021 Mar 31. COVID-19 vaccination-associated myelitis. *QJM: Int. J. Med.* 114 (8), 591–593. <https://doi.org/10.1093/qjmed/hcab069> PMID: 33787891; PMCID: PMC8083508.
- Maniscalco, G.T., Manzo, V., Di Battista, M.E., Salvatore, S., Moreggia, O., Scavone, C., et al., 2021 Aug 10. Severe multiple sclerosis relapse after COVID-19 vaccination: a case report. *Front. Neurol.* 12, 721502.
- Mathew, T., John, S.K., 2021 Dec. COVID-19 vaccine (ChAdOx1 nCoV-19 Corona virus vaccine (Recombinant)) – COVISHIELD related MS relapse. *Neuroimmunol. Reports*. 1, 100006.
- McLean, P., Trefts, L., 2021 Dec. Transverse myelitis 48 hours after the administration of an mRNA COVID 19 vaccine. *Neuroimmunol. Reports*. 1, 100019.
- Nagy, A., Alhatlani, B., 2021. An overview of current COVID-19 vaccine platforms. *Comput. Struct. Biotechnol. J.* 19, 2508–2517.
- Ndwanwe, D., Wiysonge, C.S., 2021 Aug. COVID-19 vaccines. *Curr. Opin. Immunol.* 71, 111–116.
- Notghi, A.A., Atley, J., Silva, M., 2021 Sep. Lessons of the month 1: longitudinal extensive transverse myelitis following AstraZeneca COVID-19 vaccination. *Clin. Med.* 21 (5), e535–e538.
- Ozgen Kenangil, G., Ari, B.C., Guler, C., Demir, M.K., 2021 Aug. Acute disseminated encephalomyelitis-like presentation after an inactivated coronavirus vaccine. *Acta Neurol. Belg.* 121 (4), 1089–1091.
- Pagenkopf, C., Südmeyer, M., 2021 Sep. A case of longitudinally extensive transverse myelitis following vaccination against Covid-19. *J. Neuroimmunol.* 358, 577606.
- Raknuzaman, M., Jannaty, T., Hossain, M.B., Saha, B., Dey, S.K., Shahidullah, M., 2021. Post Covid19 vaccination acute disseminated encephalomyelitis: a case report in Bangladesh. *Int. J. Med. Sci. Clin. Res. Stud.* 1 (03), 31–36.
- Rinaldi, V., Bellucci, G., Romano, A., Bozzao, A., Salvetti, M., 2021 Sep. ADEM after ChAdOx1 nCoV-19 vaccine: a case report. *Mult. Scler.* 30, 135245852110402.
- Román, G.C., Gracia, F., Torres, A., Palacios, A., Gracia, K., Harris, D., 2021. Acute transverse myelitis (ATM): clinical review of 43 patients with COVID-19-associated ATM and 3 post-vaccination ATM serious adverse events with the ChAdOx1 nCoV-19 vaccine (AZD1222). *Front. Immunol.* 12, 653786.
- Salemi, S., D'Amelio, R., 2010 Jun. Could autoimmunity be induced by vaccination? *Int. Rev. Immunol.* 29 (3), 247–269.
- Seyed Ahadi, M., Ghadiri, F., Ahraian, M.A., Naser Moghadasi, A., 2021 Aug 11. Acute attack in a patient with multiple sclerosis 2 days after COVID vaccination: a case report. *Acta Neurol. Belg.* <https://doi.org/10.1007/s13760-021-01775-2> [Internet]. [cited 2021 Oct 11]; Available from: Somers, E.C., Thomas, S.L., Smeeth, L., Hall, A.J., 2009 Jan 6. Are individuals with an autoimmune disease at higher risk of a second autoimmune disorder? *Am. J. Epidemiol.* 169 (6), 749–755.
- Tahir, N., Koorapati, G., Prasad, S., Jeelani, H.M., Sherchan, R., Shrestha, J., et al., 2021 Jul 25. SARS-CoV-2 vaccination-induced transverse Myelitis. *Cureus* 13 (7), e16624 [Internet]. [cited 2021 Sep 2]; Available from: <https://www.cureus.com/articles/63667-sars-cov-2-vaccination-induced-transverse-myelitis>.
- Vegezzi, E., Ravaglia, S., Buongarzone, G., Bini, P., Diamanti, L., Gastaldi, M., et al., 2021 Oct. Acute myelitis and ChAdOx1 nCoV-19 vaccine: casual or causal association? *J. Neuroimmunol.* 359, 577686.
- Velikova, T., Georgiev, T., 2021 Mar. SARS-CoV-2 vaccines and autoimmune diseases amidst the COVID-19 crisis. *Rheumatol. Int.* 41 (3), 509–518.
- Vera-Lastra, O., Medina, G., Cruz-Dominguez, M.D.P., Jara, L.J., Shoenfeld, Y., 2013 Apr. Autoimmune/inflammatory syndrome induced by adjuvants (Shoenfeld's syndrome): clinical and immunological spectrum. *Expert. Rev. Clin. Immunol.* 9 (4), 361–373.
- Vogrig, A., Janes, F., Gigli, G.L., Curcio, F., Negro, I.D., D'Agostini, S., et al., 2021 Sep. Acute disseminated encephalomyelitis after SARS-CoV-2 vaccination. *Clin. Neurol. Neurosurg.* 208, 106839.
- Voysey, M., Clemens, S.A.C., Madhi, S.A., Weckx, L.Y., Folegatti, P.M., Aley, P.K., et al., 2021 Jan. Safety and efficacy of the ChAdOx1 nCoV-19 vaccine (AZD1222) against SARS-CoV-2: an interim analysis of four randomised controlled trials in Brazil, South Africa, and the UK. *Lancet* 397 (10269), 99–111.

Watad, A., De Marco, G., Mahajna, H., Druyan, A., Eltity, M., Hijazi, N., et al., 2021 Apr 29. Immune-mediated disease flares or new-onset disease in 27 subjects following mRNA/DNA SARS-CoV-2 vaccination. *Vaccines*. 9 (5), 435.

World Health Organisation, 2021. WHO Coronavirus Disease (COVID-19) Dashboard. [Internet] [cited 2021 Sep 1]. Available from: <https://covid19.who.int/>.
Wraith, D.C., Goldman, M., Lambert, P.-H., 2003 Nov. Vaccination and autoimmune disease: what is the evidence? *Lancet* 362 (9396), 1659–1666.